

Unusual Diaphragmatic Rupture as A Cause of Sudden Death in A Horse

Sameeh M. Abutarbush

Department of Veterinary Clinical Sciences, Faculty of Veterinary Medicine,
Jordan University of Science and Technology, Irbid 22110, Jordan
Veterinary Medicine Department, College of Food and Agriculture,
United Arab Emirates University, Al Ain, UAE

Abstract: An 8 year old thoroughbred mare was presented with a history of sudden death. The mare was bought a month before presentation and was used for pleasure riding. Soon after she was turned out, on the day of presentation, her respiratory rate increased suddenly and started shaking. She became recumbent and died within 15 minutes. Post mortem examination revealed a 20 cm long rent and rupture of the diaphragm. There were diffuse hemorrhagic areas of the diaphragm around the rent and the edges were rough and edematous. The lungs were completely collapsed and there was severe hemothorax. The cause of death was determined to be hemorrhagic shock and suffocation due to lungs collapse. Report of this presentation for this condition is unusual.

Key words: Diaphragmatic Rupture • Hemothorax • Horse • Sudden Death

INTRODUCTION

Usually, sudden death attracts public and owners' attention and curiosity. When encountered with such case, the equine practitioner is usually exposed to a great pressure to explain the cause of sudden death.

There are two terms that describe unexplained and quick death of horses in the veterinary literature; sudden and unexpected death. Sudden death is defined as collapse and instant death within few minutes, while unexpected death is defined as finding the horse dead after having been healthy when last seen [1].

Sudden death in horses has numerous causes and some of which remains unknown despite the advancement of knowledge in equine diseases and diagnostic modalities. Lesions that are found in horses that experience sudden death are usually related to different body systems. Cardiovascular lesions included myocardial necrosis and rupture of the aorta, pulmonary trunk, atrium and mitral cordae tendineae. Lesions of the respiratory system include pulmonary hemorrhage, pneumothorax and acute pulmonary

edema due to acute adverse drug reactions. Skull fracture, spinal cord trauma and intracranial hemorrhage are usually seen in horses that die suddenly due to diseases nervous system. Per-acute colitis is the only lesion found in the gastrointestinal system and explains sudden death. Other miscellaneous cases of sudden death are associated with electrocution, lightning strike and gunshot injuries [1].

Generally, diaphragmatic defect is uncommon finding in horses and a rare cause of sudden death. It can be congenital or acquired. The exact pathogenesis remains unknown and speculative in most cases. Affected horses usually have a history of severe exercise, parturition and external trauma. Clinical signs vary and affected horses are mainly presented for respiratory distress and/or show signs of abdominal pain. Diagnosis of diaphragmatic rent and rupture is very challenging and need careful history and examination. Usually, it needs diagnostic modalities that might not be present in the general veterinary practices. Treatment is complicated and requires surgical intervention. Even if presented early in the course of the disease, it usually does not have good prognosis [2].

MATERIALS AND METHODS

Case History: A post mortem examination was done on an 8 year old thoroughbred mare with a history of sudden death. The mare was bought a month before presentation and was used for pleasure riding. There are another 3 mares and 1 stallion kept on the premises. The owner reported that the mare was used for short race in the past with no history of previous illness. The mare was not pregnant and has an unknown history of previous foaling. She was dewormed and vaccinated regularly. On the day of presentation, she was turned out from her stall to a small pasture. She appeared bright alert and responsive. Soon after she was turned out to the pasture, she started doing the routine playing, jumping and kicking as usual. Few minutes later, her respiratory rate increased suddenly and started shaking. She became recumbent and died after she had froth coming out from her nose and mouth. The duration of illness was 15 minutes.

Clinical Findings: On presentation, the mare was recumbent on her left side. She had 2/5 body condition score and there were no sign of external trauma. Her mucous membranes were pale. Upon opening of the abdominal cavity, the gastrointestinal tract appeared intact and normal in color. The large colon had moderate amount of feed. There were no intestinal accidents, rupture, strangulation or perforation. However, there were a few blood clots scattered throughout the abdomen and moderate amount of blood in the abdominal cavity. The blood did not appear to originate from any of the major abdominal blood vessels. Examination of the cranial part of the abdomen revealed a 20 cm long rent and rupture of the diaphragm. The rent was located at the left side of the sternal part of the diaphragm. The rent was wide open and you could see part of the pericardium and heart through it (Figure 1). No intestines or other organs had gone through the ruptured diaphragm to the thoracic cavity. There were diffuse hemorrhagic areas of the diaphragm around the rent and the edges were rough and edematous. Examination of the thoracic cavity revealed the presence of large blood clots and severe hemothorax (Figure 2). The lungs were completely flaccid and collapsed with no evidence of tissue trauma (Figure 3). The rib cage appeared intact with no evidence of perforation or fracture. The major blood vessels of the thoracic cavity were examined and appeared intact. The cause of death was determined to be hemorrhagic shock and suffocation due to lungs collapse.

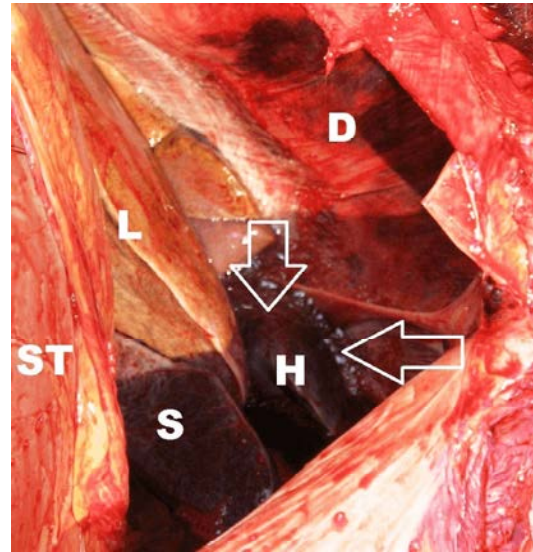


Fig. 1: Rupture of the diaphragm in a horse. Note that part of the pericardium and heart (H) is seen through the rent which is outlined by arrows. Diaphragm (D), stomach (ST), liver (L), spleen (S).

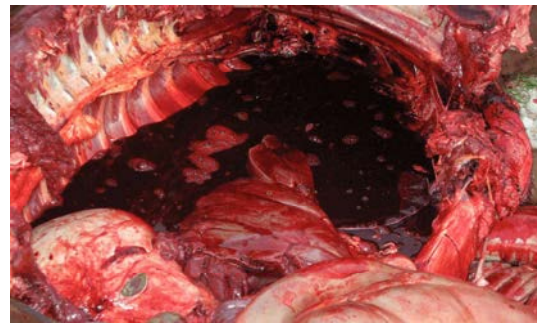


Fig. 2: Severe hemothorax in a case of ruptured diaphragm in a horse.

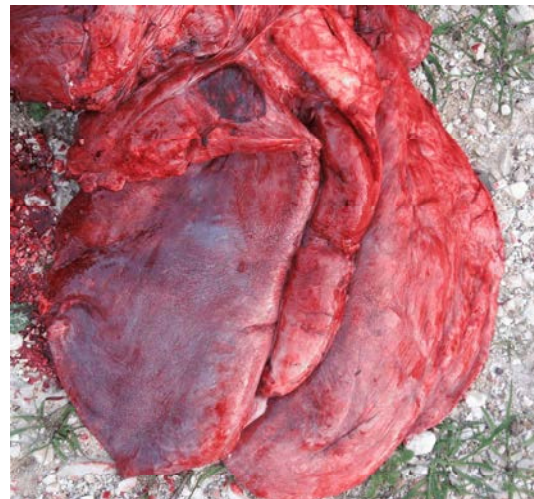

Fig. 3: Complete pulmonary collapse in a case of ruptured diaphragm in a horse.

DISCUSSION

When compared to cases of diaphragmatic rupture and hernia reported in the literature, this clinical report documents an unusual diaphragmatic rupture in a horse. Unusual aspects of this case include absence of previous predisposing factors in the history, such as trauma, gastrointestinal distension, unobserved pasture confinement, natural covering, dystocia, or severe exercise [3-6]. In addition, it has a very short duration of illness (15 minutes) and there was no bowel and other organs herniation through the rupture. In a study that reported the rupture of the diaphragm in 4 cases, the duration of illness ranged from 6 hours to 4 days [7], while in another one was 7 days [3]. Diaphragmatic defects that lead to clinical signs in adult horses are associated with visceral herniation. This was absent in the present case. Diaphragmatic defects that are not associated with visceral herniation are known to occur in foals and are called diaphragmatic rents. These are usually congenital in origin [2].

The exact cause of the rent in this mare remains unknown. Diaphragmatic rent and defects in horses are thought to be associated with trauma or congenital defects [2]. There was no history or findings suggestive of trauma in this mare. Although this was not what happened in this mare, some authors suggests that the time from rent formation to identification depends on the occurrence of other events such as visceral herniation through the rent, especially after colic attacks that would lead to increased intra-abdominal pressure [2]. Perhaps this mare was suffering from an unobserved congenital defect that she lived with until this presentation. The mare was reported to run, jump and kick such as any other normal horse that is turned out after being in the stall. This could have led to rupture of a previous weak area or defect in the diaphragm.

Report of this presentation for diaphragmatic rent or rupture is unusual. Diaphragmatic rent should be considered in horses with sudden death without previous reported prolonged history of obvious signs related to the respiratory and digestive system.

REFERENCES

1. Brown, C.M. and T.P. Mullaney, 1989. Sudden and unexpected death. In: Brown CM, editor. Problems in Equine Medicine. Philadelphia, USA: Lea and Febiger; pp: 67-80.
2. Romero, A.E. and D.H. Rodgeron, 2010 . Diaphragmatic herniation in the horse: 31 cases from 2001-2006. *Can. Vet. J.*, 51: 1247-50.
3. Goehring, L.S., L.R. Goodrich and M.J. Murray, 1999. Tachypnea associated with a diaphragmatic tear in a horse. *Equine Vet. J.*, 31: 443-445.
4. Wimberly, H.C., E.J. Andrews and W.M. Haschek, 1977. Diaphragmatic hernias in the horse: a review of the literature and an analysis of six additional cases. *J. Am Vet. Med. Assoc.* 170(12): 1404-1407.
5. Bristol, D.G., 1986. Diaphragmatic hernias in horses and cattle. *Comp. Cont. Educ. Pract. Vet.*, 8: 5407-5412.
6. Everett, K.A., M.K. Chaffin and S.P. Brinsko, 1992. Diaphragmatic herniation as a cause of lethargy and exercise intolerance in a mare. *Cornell. Vet.*, 82: 217-223.
7. Pearson, H., P.J. Pinsent, L.R. Polley and A. Waterman, 1977. Rupture of the diaphragm in the horse. *Equine Vet. J.*, 9: 32-6.